International Journal of Advanced Multidisciplinary Research and Educational Development ISSN: **3107-6513**
Volume 2 - Issue 6 | November - December 2026 | www.ijamred.com

Choroidal Neovascularization after Phacoemulsification in Dry Age-Related Macular Degeneration

A Case Report

Samah Said Shirri[#1]

[#1]*Ophthalmologist, Zarqa New Governmental Hospital, Ministry of Health, Jordan*

[1]samah.shirri@gmail.com

Abstract—

Whether cataract surgery accelerates the conversion of dry age-related macular degeneration to the neovascular form remains controversial. We describe a 68-year-old woman with diabetes mellitus and uncontrolled hypertension and hyperlipidemia who presented with long-standing blurred vision in the left eye. The eye was hypermetropic with an axial length of 21.00 mm and had a cataract and multiple macular drusen consistent with dry age-related macular degeneration. Uneventful phacoemulsification with intraocular lens implantation was performed. Visual acuity was 0.5 at one week but fell to counting fingers at 2 m at one month. Subretinal hemorrhage and macular thickening were present, and optical coherence tomography and optical coherence tomography angiography confirmed type 2 choroidal neovascularization. Intravitreal aflibercept 2 mg was given every four weeks for three months and then every eight weeks. After three injections visual acuity improved to 0.2, with regression of neovascularization and early retinal scarring. Eyes with drusen may develop exudative conversion soon after cataract surgery. Although causality cannot be proven from one case, careful preoperative macular imaging, counseling, and early postoperative review are advisable, and prompt anti-vascular endothelial growth factor therapy can improve vision.

Keywords—Choroidal neovascularization; age-related macular degeneration; phacoemulsification; cataract surgery; aflibercept; optical coherence tomography angiography

I. INTRODUCTION

Age-related macular degeneration (AMD) and cataract are two of the most common ocular diseases of the elderly, and many patients have both conditions when cataract surgery is considered [1]. Neovascular (wet) AMD is characterized by choroidal neovascularization (CNV), in which new vessels grow from the choroid through Bruch's membrane. In type 2 (classic) CNV, the vessels cross the retinal pigment epithelium (RPE) and extend into the subretinal space.

Whether phacoemulsification worsens AMD, increases the risk of progression from dry to wet disease, or reactivates a pre-existing CNV has been debated for years, and the results of published studies are inconsistent [2]–[6]. We report a patient with dry AMD who developed hemorrhagic type 2 CNV within one month of uneventful phacoemulsification, and we discuss the proposed mechanisms and the available evidence.

II. MATERIALS AND METHODS

A. Patient and Clinical Assessment

A 68-year-old woman presented with long-standing blurred vision in her left eye. Her medical history included diabetes mellitus of three years' duration that was well controlled (glycated hemoglobin 6%), and hypertension and hyperlipidemia, each of 20 years' duration and uncontrolled. Her ocular history was notable for phacoemulsification of the right eye in 2016, complicated by posterior capsule rupture, with a single-piece intraocular lens (IOL; +30.00 D) placed in the ciliary sulcus.

Uncorrected visual acuity (decimal notation) was 0.4 in the right eye (best-corrected 0.6) and 0.1 in the left eye (best-corrected 0.4). Auto-refraction was +0.25/−3.50 × 125 in the right eye and +8.00/−0.50 × 35 in the left eye; the large refractive difference between the eyes made spectacle correction intolerable. Intraocular pressure was 12 mmHg (1.6 kPa) in both eyes.

Slit-lamp examination showed clear corneas and deep, quiet anterior chambers without iris neovascularization in both eyes, with Van Herick grade 4 bilaterally. The right eye had a stable sulcus IOL. The left eye had a grade 2 posterior subcapsular cataract and grade 2 nuclear sclerosis, with moderate pupillary dilatation. Fundus examination showed flat retinae and normal-looking optic discs (vertical cup-to-disc ratio 0.4) in both eyes, with grade 2 hypertensive retinopathy. Multiple small to intermediate macular drusen with hyper- and hypopigmentary changes, suggestive of dry AMD, were present bilaterally and were more severe in the left eye.

B. Biometry and Imaging

The axial length of the left eye was 21.00 mm, and anterior chamber depth measured by Scheimpflug tomography (Pentacam, Oculus Optikgeräte GmbH, Wetzlar, Germany) was 3.20 mm. Biometry of the left eye gave an IOL power of +30.00 D (Hoffer Q formula, A-constant 118.4). Baseline macular optical coherence tomography (OCT) was obtained to establish a reference before surgery (Fig. 1). OCT and OCT angiography (OCTA) were used to assess the macula after surgery.

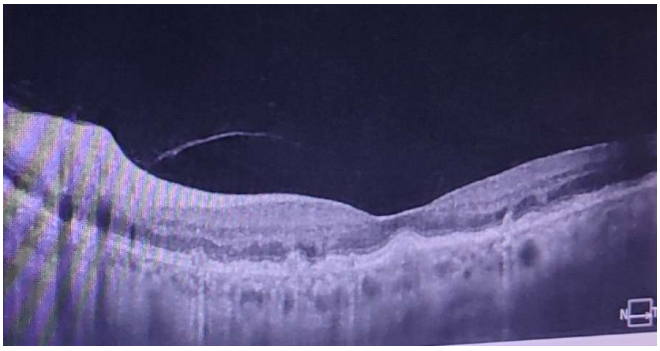

Fig. 1. Baseline macular optical coherence tomography B-scan of the left eye before cataract surgery.

C. Surgery

After counseling, the left eye underwent uneventful phacoemulsification with IOL implantation (+30.00 D).

III. Results and Discussion

A. Postoperative Course and Imaging Findings

One week after surgery, visual acuity was 0.5 and the IOL was stable. At the one-month visit, the patient reported blurred vision in the left eye, and visual acuity had fallen to counting fingers at 2 m, without improvement on refraction. Fundus examination revealed subretinal hemorrhage, macular thickening, and multiple drusen, consistent with wet (hemorrhagic) AMD.

OCT showed a fibrovascular lesion crossing the RPE into the subretinal space, with adjacent subretinal hyperreflective material, subretinal fluid, and macular thickening, in keeping with classic (type 2) CNV (Fig. 2). OCTA showed a sea-fan neovascular complex within the normally avascular outer retina, together with altered choriocapillaris signal beneath the lesion.

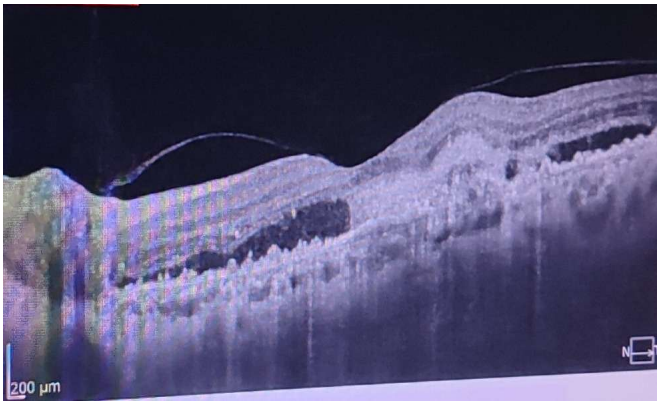

Fig. 2. Macular optical coherence tomography B-scan of the left eye one month after surgery, showing a fibrovascular lesion that crosses the retinal pigment epithelium into the subretinal space (type 2 choroidal neovascularization) with subretinal fluid.

B. Treatment and Outcome

Intravitreal aflibercept (2 mg/0.05 mL) was started, given every 4 weeks for the first 3 months and then every 8 weeks. After three injections, visual acuity improved from counting fingers to 0.2+. Macular OCT showed improvement in overall retinal thickness with regression of the neovascularization and early signs of retinal scarring (Fig. 3). The clinical course is summarized in Table I.

TABLE I
Timeline of Visual Acuity and Management of the Left Eye

No.	Time Point	Left-Eye Visual Acuity (decimal)[a]	Findings and Action
1	Baseline	0.1 (best-corrected 0.4)	Cataract and dry AMD with drusen; baseline OCT obtained
2	1 week after surgery	0.5	Stable IOL position
3	1 month after surgery	Counting fingers at 2 m, no improvement with refraction	Subretinal hemorrhage and macular thickening; type 2 CNV on OCT and OCTA; aflibercept started
4	After three injections	0.2+	Visual improvement; regression of neovascularization on follow-up OCT (Fig. 4)

[a] Visual acuity is given in decimal notation.

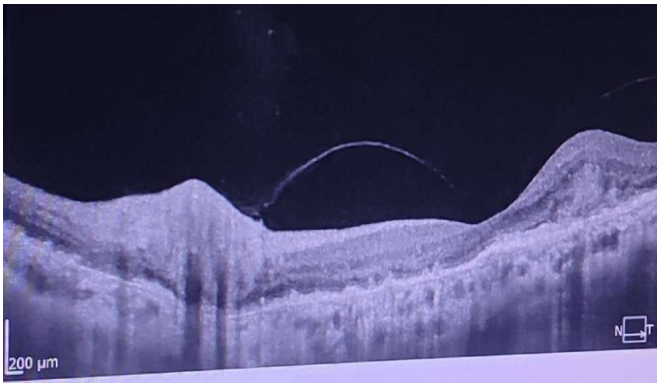

Fig. 3. Macular optical coherence tomography of the left eye after three intravitreal aflibercept injections.

C. Discussion

Our patient had dry AMD, with multiple drusen and pigmentary changes that were more severe in the left eye, and developed hemorrhagic type 2 CNV within one month of uneventful phacoemulsification. The temporal relationship raises the question of whether surgery triggered the conversion or merely coincided with the natural course of the disease, and a single case cannot distinguish between the two.

Several mechanisms have been proposed to link cataract surgery with AMD progression: light toxicity from the bright illumination of the operating microscope, surgery-induced release of inflammatory mediators, postoperative changes in choroidal thickness, and increased retinal exposure to short-wavelength light once the cataractous lens is removed. In patients with diabetic retinopathy, aqueous vascular endothelial growth factor (VEGF)-165 rose from a median of 68 pg/mL before surgery to 723 pg/mL on the first postoperative day and took about three months to return to normal [7]. Changes in subfoveal choroidal thickness after uncomplicated phacoemulsification have also been studied in relation to operative time and phacoemulsification time and power [8].

The clinical evidence is inconsistent. In the Age-Related Eye Disease Study cohort of 4577 participants (8050 eyes), cataract surgery had no clear effect on progression to advanced AMD; for right eyes the hazard ratio for neovascular AMD was 1.20 (95% confidence interval 0.82–1.75) [2]. A prospective angiographic study of 108 patients with nonneovascular AMD

found new neovascular AMD in 9 of 71 eyes (12.7%) at 12 months, but in only 3 of 65 eyes (4.6%) after excluding events already visible on week-1 angiography. The authors concluded that many cases of presumed progression after surgery may have been present before surgery but obscured by lens opacity [3]. In contrast, a small retrospective analysis reported development or exacerbation of CNV in 18 of 25 eyes (72%) that underwent cataract surgery versus 9 of 25 eyes (36%) in which surgery was deferred [5]. A UK cohort of 327 eyes with AMD complicated by CNV found that phacoemulsification had no clinically significant effect on CNV activity, judged by intravitreal injection frequency [6].

A clear answer is difficult to obtain for several reasons. Patients with cataract and AMD belong to similar age groups, and the two diseases may share risk factors. Patients with these shared risk factors may also have denser cataracts, which prompt surgery earlier. In addition, dense cataracts can impede the detection of AMD before surgery, so that disease already present may be wrongly attributed to the operation.

Cataract surgery is generally favored in patients with AMD, because removing a visually significant cataract can improve visual acuity, contrast and color sensitivity, and peripheral vision, and allows AMD progression to be detected more easily. Active AMD should be controlled before elective cataract surgery. In eyes receiving regular anti-VEGF therapy with good control, surgery can be performed between injection visits, and an anti-VEGF injection within one month of surgery may be considered to limit postoperative edema, although there is no definite evidence on the ideal timing. Patients should be told clearly that distorted vision, central scotoma, and poor near vision caused by AMD will not be cured by cataract surgery.

OCTA proved valuable in our patient. It is a noninvasive, clinic-based imaging method that allows CNV to be diagnosed, classified, and localized by segmenting the outer retina and the choriocapillaris. Type 2 CNV appears as a neovascular network that arises from the choroid, crosses the RPE–Bruch's membrane complex, and grows into the subretinal space.

This report has limitations. It describes a single patient, so causality cannot be inferred. The interval between the baseline OCT and surgery was 2 months, so subclinical CNV before surgery cannot be excluded.

IV. Conclusions

This case illustrates that eyes with drusen can develop exudative CNV soon after cataract surgery. Thorough preoperative evaluation, detailed macular imaging, and informed counseling about expected outcomes are essential in elderly patients with AMD and multiple comorbidities. Clinicians should recognize the possibility of AMD exacerbation after surgery and re-examine patients early, and OCTA is a useful tool for confirming and localizing CNV. Prompt anti-VEGF therapy can stabilize and improve visual function in hemorrhagic AMD.

Declarations

Ethical considerations. Written informed consent for publication of this case report and the accompanying images was obtained from the patient, and patient confidentiality has been maintained; all identifying information has been removed from the images. *Funding.* None. *Conflict of interest.* None.

Acknowledgment

None.

References

[1] H. Casparis, K. Lindsley, I.C. Kuo, S. Sikder, and N.M. Bressler, "Surgery for cataracts in people with age-related macular degeneration," Cochrane Database Syst. Rev., no. 2, art. no. CD006757, 2017, doi: 10.1002/14651858.CD006757.pub4.

[2] E.Y. Chew et al., "Risk of advanced age-related macular degeneration after cataract surgery in the Age-Related Eye Disease Study: AREDS report 25," Ophthalmology, vol. 116, no. 2, pp. 297-303, 2009, doi: 10.1016/j.ophtha.2008.09.019.

[3] L.M. Dong et al., "Progression of age-related macular degeneration after cataract surgery," Arch. Ophthalmol., vol. 127, no. 11, pp. 1412-1419, 2009, doi: 10.1001/archophthalmol.2009.152.

[4] Z. Chen, Y. Zeng, and F. Tian, "Effect of cataract surgery on the progression of age-related macular degeneration," Medicine (Baltimore), vol. 101, no. 44, art. no. e31566, 2022, doi: 10.1097/MD.0000000000031566.

[5] P. Monaco et al., "Cataract surgery and neovascular age-related macular degeneration development or exacerbation: a retrospective analysis," Invest. Ophthalmol. Vis. Sci., vol. 60, no. 9, p. 1139, 2019 (ARVO annual meeting abstract).

[6] H.D.J. Hogg et al., "An observational clinical study of the influence of phacoemulsification on choroidal neovascular membrane activity in age related macular degeneration," Eye, 2021, doi: 10.1038/s41433-021-01653-4.

[7] J.I. Patel, P.G. Hykin, and I.A. Cree, "Diabetic cataract removal: postoperative progression of maculopathy - growth factor and clinical analysis," Br. J. Ophthalmol., vol. 90, no. 6, pp. 697-701, 2006, doi: 10.1136/bjo.2005.087403.

[8] P. Tranos et al., "The effects of uneventful phacoemulsification on subfoveal choroidal thickness," Ophthalmol. Ther., vol. 12, no. 6, pp. 3013-3023, 2023, doi: 10.1007/s40123-023-00796-9.