Paracentral Acute Middle Maculopathy in a Young Woman: A Case Report

Malak Faraj Harahsheh[#1]
[#]Ophthalmologist, Zarqa New Governmental Hospital, Ministry of Health, Jordan
[1]malak_harahsheh@yahoo.com

Abstract—

Paracentral acute middle maculopathy is an optical coherence tomography finding that reflects ischemia of the middle retinal layers and typically presents with a paracentral scotoma. We report a 38-year-old woman with hypertension and asthma who presented with a two-year history of a small cloud-like paracentral field defect in the right eye, with minimal recent improvement and no pain, redness, trauma, or previous similar episodes. Visual acuity was 0.8 in both eyes, with normal pupillary responses, color vision, and intraocular pressure. Fundus examination showed subtle perifoveal discoloration in the right macula, mild vessel tortuosity, and early hypertensive changes in both eyes, while the left macula was normal. Multimodal imaging with optical coherence tomography, fluorescein angiography, and optical coherence tomography angiography were performed. The right eye showed reduced flow in the deep capillary plexus, and the findings were considered consistent with paracentral acute middle maculopathy, with acute macular neuroretinopathy in the differential diagnosis. No specific treatment exists, and care centers on systemic vascular risk assessment and follow-up. This case shows that the condition can occur in a young patient with modest vascular risk factors and may be diagnosed late.

Keywords—paracentral acute middle maculopathy; acute macular neuroretinopathy; paracentral scotoma; optical coherence tomography angiography; deep capillary plexus

I. INTRODUCTION

Paracentral acute middle maculopathy (PAMM) is an optical coherence tomography (OCT) finding first reported by Sarraf and colleagues in 2013 and interpreted as a more superficial variant of acute macular neuroretinopathy (AMN) [1]. It is characterized by hyperreflective, band-like lesions at the level of the inner nuclear layer (INL) in patients with an acute negative scotoma, and it evolves into thinning of the INL without involvement of the outer retina [2]. The name reflects both the parafoveal position of the grey lesions on near-infrared reflectance imaging and the localization of the abnormality to the middle layers of the retina [2].

PAMM can occur as an isolated phenomenon or as a complication of an underlying retinal vasculopathy or systemic disease [2]. It is reported most often in patients in their fifties and sixties, but it may also develop in younger and otherwise healthy individuals. We report a 38-year-old woman with hypertension who presented with a two-year history of a paracentral scotoma in the right eye, and we describe her multimodal imaging findings and the differential diagnosis.

II. CASE PRESENTATION

A. Clinical History

A 38-year-old woman presented with a two-year history of a paracentral field defect in the right eye, which she described as a small cloud over the eye. Her symptoms had improved minimally over the preceding few months. She denied pain, redness, trauma, and previous similar attacks. Her past medical history included hypertension and asthma, and she had undergone cholecystectomy. Her medications were aspirin, enalapril maleate, a formoterol and budesonide inhaler, and a salbutamol inhaler. She had no known allergies and was a passive smoker.

B. Ophthalmic Examination

Visual acuity was 0.8 in both eyes. Extraocular movements were full and painless, and the conjunctiva, sclera, and cornea were normal in both eyes. The anterior chamber was deep and quiet, and the pupils were round, regular, and reactive without a relative afferent pupillary defect. Early nuclear sclerosis was present in both lenses. Intraocular pressure was 14 mmHg in the right eye and 15 mmHg in the left eye, and color vision was normal in both eyes (Table I).

TABLE I. ANTERIOR SEGMENT EXAMINATION FINDINGS

Parameter	Right eye	Left eye
Visual acuity	0.8	0.8
Extraocular movements	Full, painless	Full, painless
Conjunctiva and sclera	Normal	Normal
Cornea	Clear	Clear
Anterior chamber	Deep and quiet	Deep and quiet
Pupil	Round, regular, reactive; no afferent defect	Round, regular, reactive; no afferent defect
Lens	Early nuclear sclerosis	Early nuclear sclerosis
Intraocular pressure (mmHg)	14	15
Color vision	Normal	Normal

ISSN: **3107-6513**

C. Fundus Examination

Both optic discs were normal and well perfused, without edema or pallor, and the cup-to-disc ratio was 0.2 in each eye. The right macula showed subtle perifoveal discoloration, whereas the left macula was normal. Mild vascular tortuosity and early hypertensive changes were present in both eyes (Fig. 1).

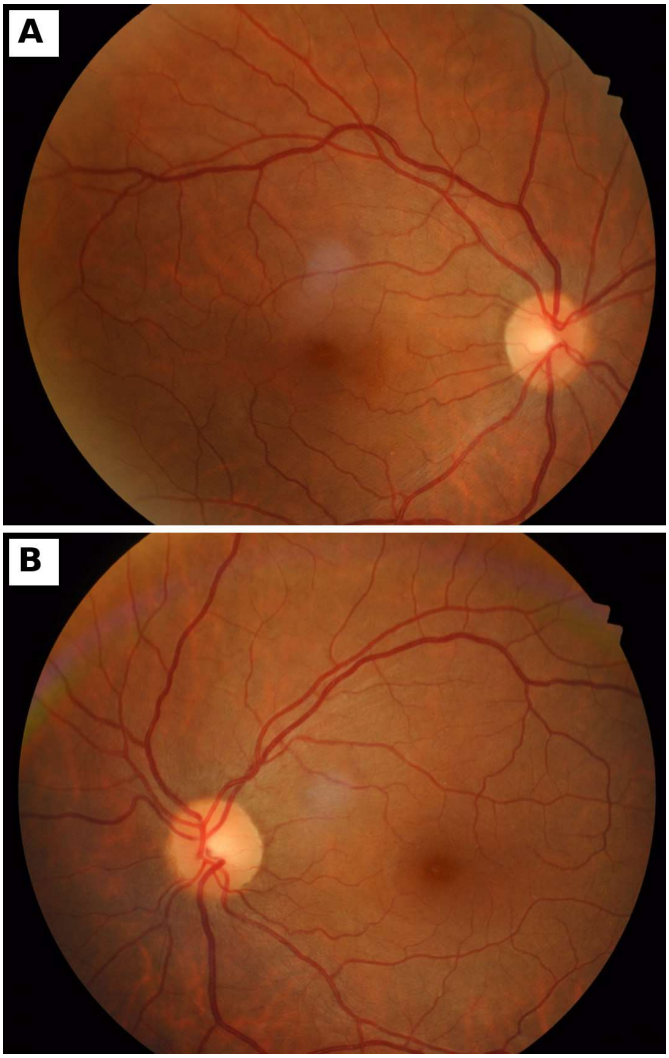

Fig. 1. Color fundus photographs of the right eye (A) and left eye (B).

D. Multimodal Imaging

Macular OCT showed a central subfield thickness of 222 µm in the right eye and 247 µm in the left eye, with a minimum foveal thickness of 194 µm and 204 µm, respectively. In the right eye, total retinal thickness in the nasal inner sector (278 µm) fell below the first percentile of the device normative database, whereas all sectors of the left eye were within normal limits (Fig. 2). Early-phase fluorescein angiography frames of the right eye are shown in Fig. 3.

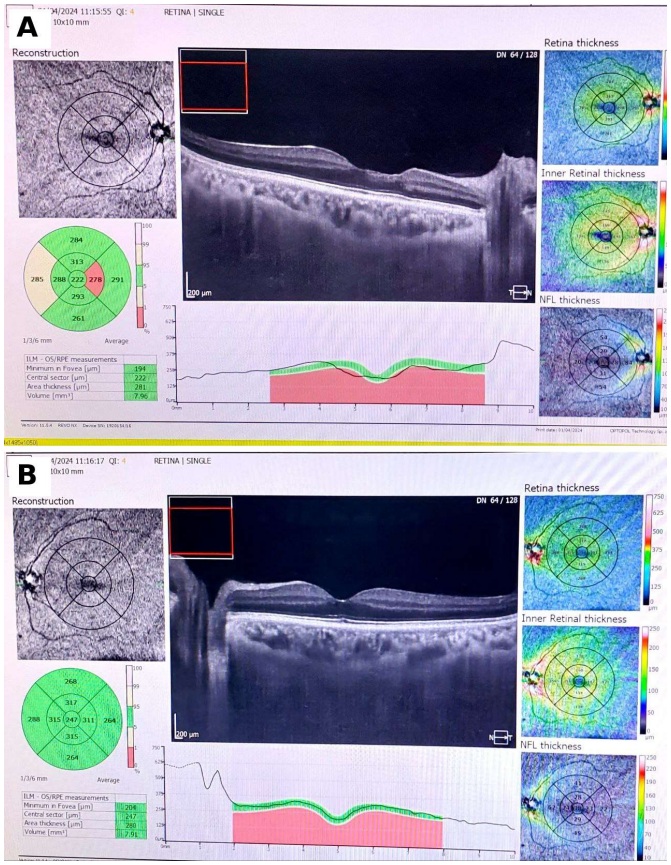

Fig. 2. Macular OCT of the right eye (A) and left eye (B), with thickness maps.

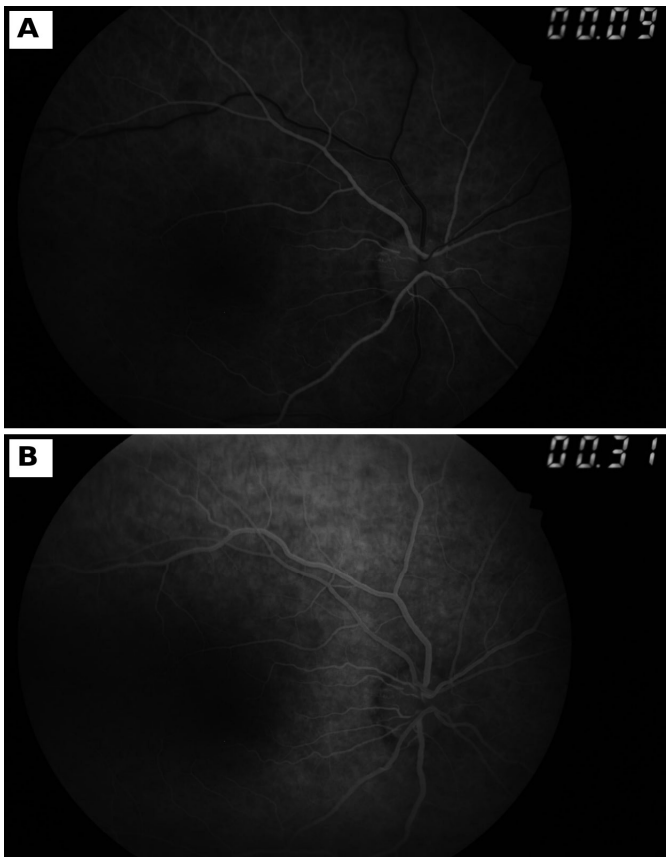

Fig. 3. Fluorescein angiography of the right eye at 9 seconds (A) and 31 seconds (B).

OCT angiography (3 × 3 mm) of the right eye showed reduced flow signal in the deep capillary plexus, centered on and extending nasal to the foveal avascular zone, with a smaller patchy area of reduced signal in the superficial capillary plexus nasal to the fovea. The superficial and deep capillary plexuses of the left eye appeared normal (Fig. 4).

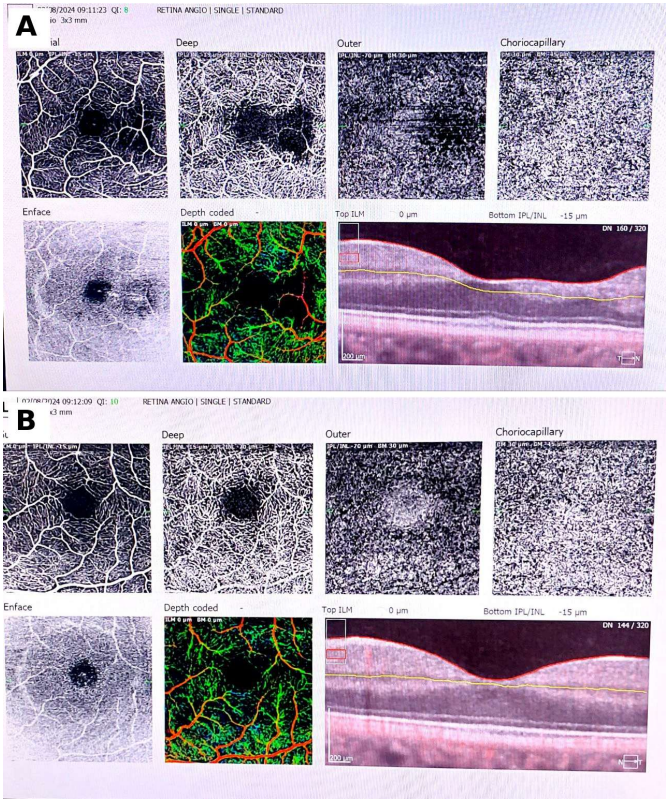

Fig. 4. OCT angiography of the right eye (A) and left eye (B): superficial, deep, outer retina, and choriocapillaris slabs, with en face and depth-coded images.

III. Discussion

A. Diagnosis and Differential Diagnosis

PAMM and AMN both present with paracentral scotomas and hyporeflective paracentral lesions on infrared imaging, but they can be distinguished on spectral-domain OCT [2]. AMN, originally described by Bos and Deutman in 1975, shows hyperreflectivity of the outer plexiform and outer nuclear layers. Over time the outer nuclear layer reflectivity recovers, and the lesion progresses to disruption of the inner segment/outer segment and outer segment/retinal pigment epithelium junctions with chronic thinning of the outer nuclear layer [3], [4]. In contrast, PAMM involves the INL and leads to INL thinning without outer retinal involvement [1].

OCT angiography has shown that both conditions are associated with capillary occlusion, although the plexus primarily affected remains debated. Using projection-resolved OCT angiography, PAMM lesions were associated with reduced flow in the middle and deep capillary plexuses, with additional superficial plexus involvement in some eyes, whereas AMN lesions were associated with reduced deep capillary plexus flow alone [5]. In our patient, OCT angiography showed a deep capillary plexus flow deficit with patchy superficial involvement in the right eye, in keeping with this pattern. Because she presented two years after symptom onset, the acute hyperreflective phase would be expected to have passed, and the focal reduction in retinal thickness in the right eye may represent the chronic thinning that follows PAMM.

B. Etiology and Risk Factors

The exact etiology of PAMM is unknown. Patients are typically in their late fifties and sixties, particularly when it complicates a retinal vasculopathy or systemic disease, but idiopathic cases occur in younger and otherwise healthy people [2]. Reported associations include systemic cardiovascular risk factors, retinal vascular occlusions, diabetic retinopathy, retinal vasculitis, sickle cell retinopathy, hypercoagulability, and hypertension, as well as vasoconstrictors such as caffeine and epinephrine, oral contraceptive use, and, in some reports, COVID-19 infection or vaccination [2]. Compared with AMN, PAMM has been associated more often with older, male, and vasculopathic patients, while AMN tends to affect younger women [2]. A shared mechanism may be sudden changes in blood pressure that overcome autoregulation of the deep capillary plexus or choriocapillaris [2]. Our patient was younger than the typical PAMM population, but she had hypertension with early hypertensive retinal changes, which may have contributed to deep capillary plexus ischemia.

C. Management and Prognosis

No treatment is currently established for PAMM, and symptomatic scotomas may fade but are usually persistent [2]. Because PAMM is often associated with other vasculopathic conditions, patients should be screened for local and systemic disease, including retinal vessel occlusions, carotid artery disease, diabetes, hypertension, and giant cell arteritis or other vasculitides. Careful follow-up is also important, because diffuse PAMM lesions can mask occult retinal occlusions that further threaten vision [2]. PAMM can be the only presenting sign of a retinal vascular occlusion, as described with cilioretinal artery occlusion, branch retinal artery occlusion, and central retinal vein occlusion [2].

IV. Conclusion

PAMM should be considered in young patients with a persistent paracentral scotoma and a subtle or near-normal fundus, including those with modest vascular risk factors such as hypertension. Multimodal imaging with OCT and OCT angiography is essential for diagnosis, for distinguishing PAMM from AMN, and for directing the search for underlying systemic vascular disease. As no specific treatment exists, management rests on control of systemic risk factors and regular follow-up.

Declarations

Ethical considerations. Written informed consent for publication of this case report and the accompanying images was obtained from the patient, and patient confidentiality has been maintained; all identifying information has been removed from the images.

Funding. None.

Conflict of interest. None.

ACKNOWLEDGMENT

None.

REFERENCES

[1] D. Sarraf, E. Rahimy, A. A. Fawzi, E. Sohn, I. Barbazetto, D. N. Zacks, R. A. Mittra, J. M. Klancnik Jr., S. Mrejen, N. R. Goldberg, R. Beardsley, J. A. Sorenson, and K. B. Freund, "Paracentral acute middle maculopathy: a new variant of acute macular neuroretinopathy associated with retinal capillary ischemia," JAMA Ophthalmol., vol. 131, no. 10, pp. 1275–1287, 2013.

[2] "Paracentral acute middle maculopathy," EyeWiki, American Academy of Ophthalmology. [Online]. Available: https://eyewiki.org.

[3] P. J. Bos and A. F. Deutman, "Acute macular neuroretinopathy," Am. J. Ophthalmol., vol. 80, no. 4, pp. 573–584, 1975.

[4] "Acute macular neuroretinopathy," EyeWiki, American Academy of Ophthalmology. [Online]. Available: https://eyewiki.org.

[5] S. Chu, P. L. Nesper, B. T. Soetikno, S. J. Bakri, and A. A. Fawzi, "Projection-resolved OCT angiography of microvascular changes in paracentral acute middle maculopathy and acute macular neuroretinopathy," Invest. Ophthalmol. Vis. Sci., vol. 59, no. 7, pp. 2913–2922, 2018.